



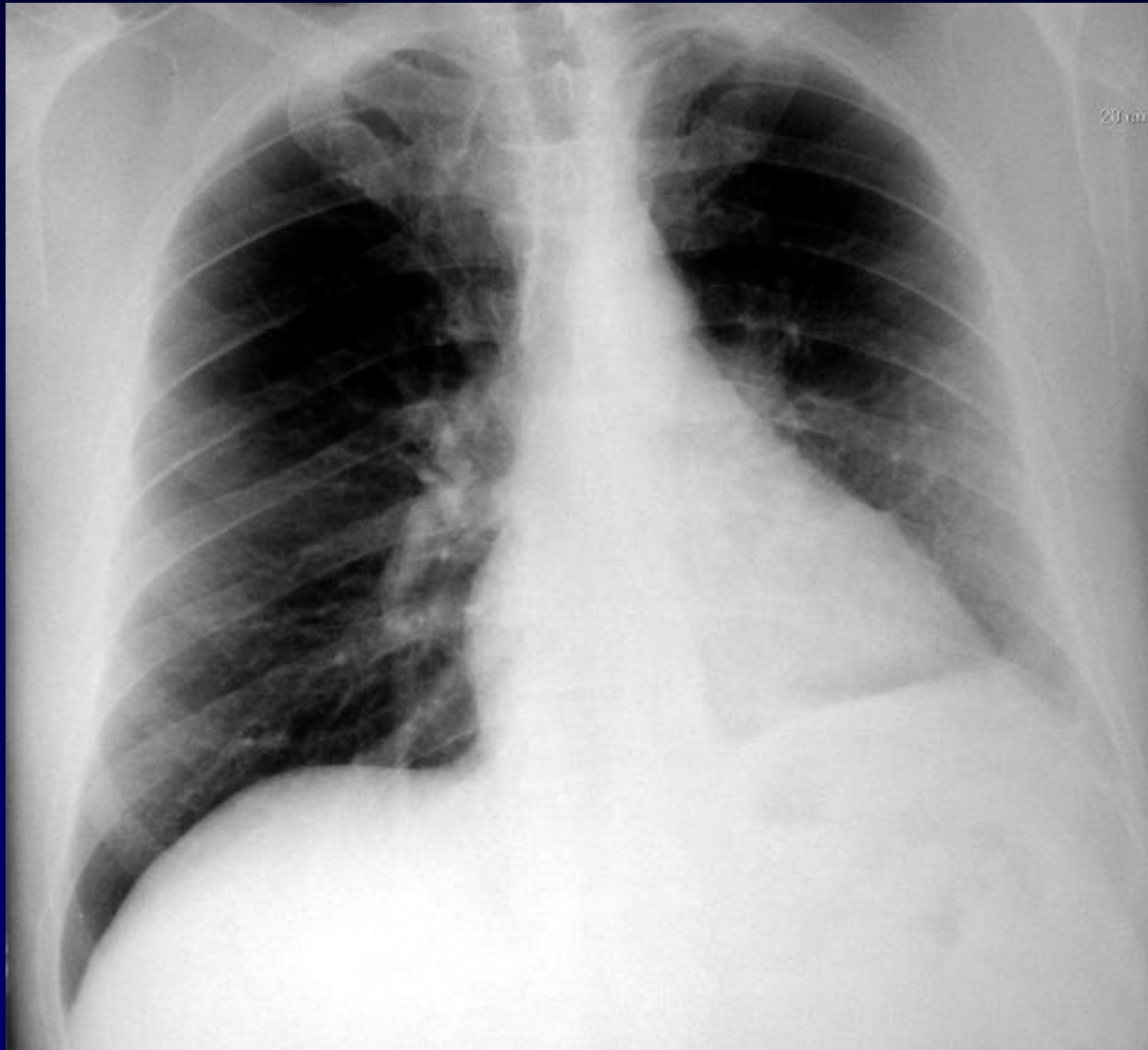
Dossier 6

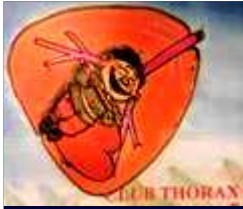**J GIRON
P FAJADET**

Homme de 55 ans

Radiofréquence pour fibrillation auriculaire en 1998

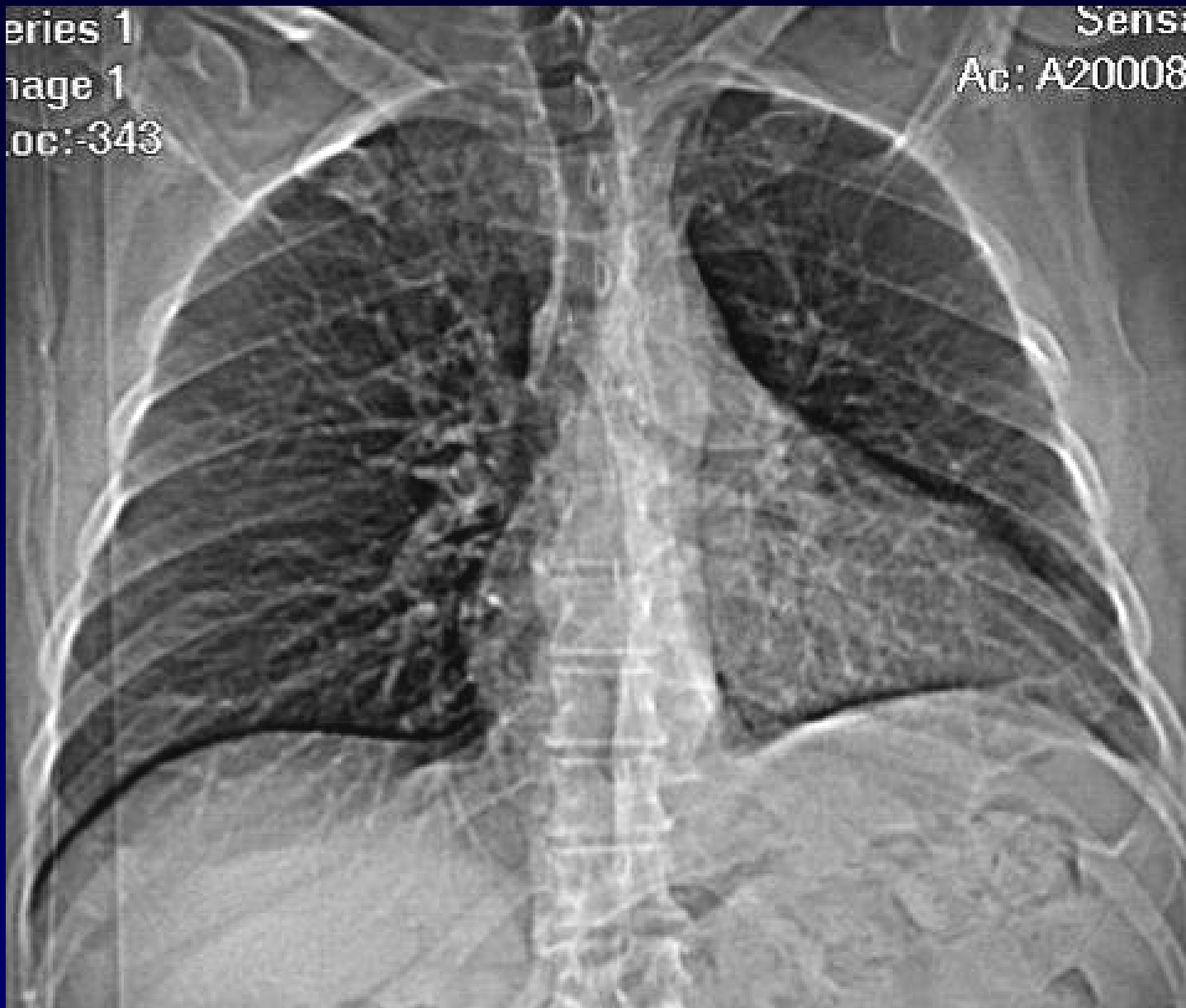**Stent de la veine pulmonaire lobaire supérieure
gauche**





Series 1
Image 1
Loc: -343

Sens
Ac: A20008



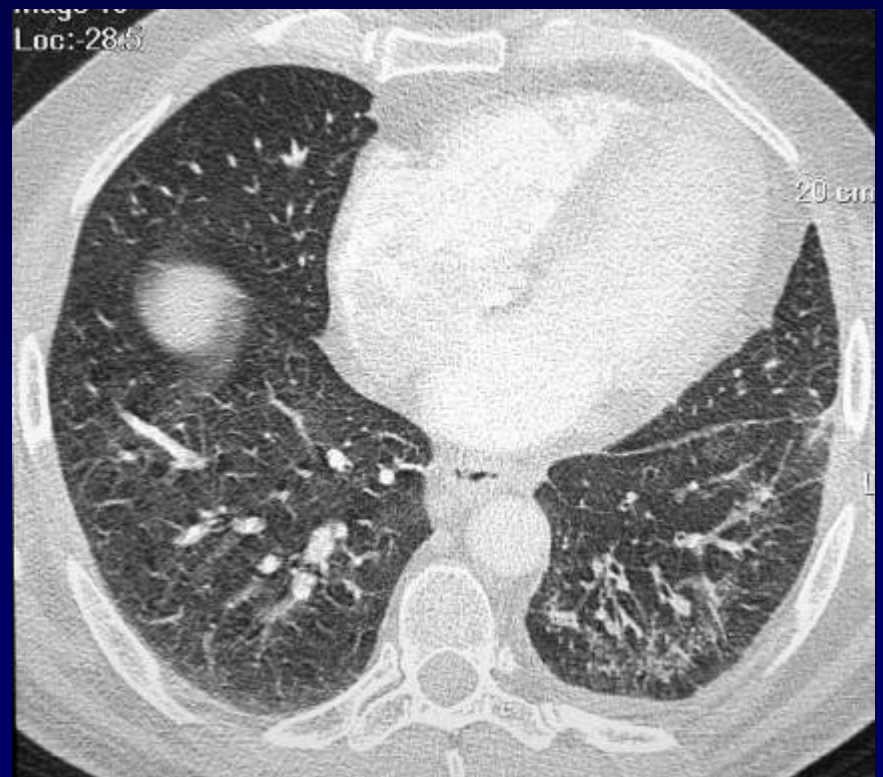
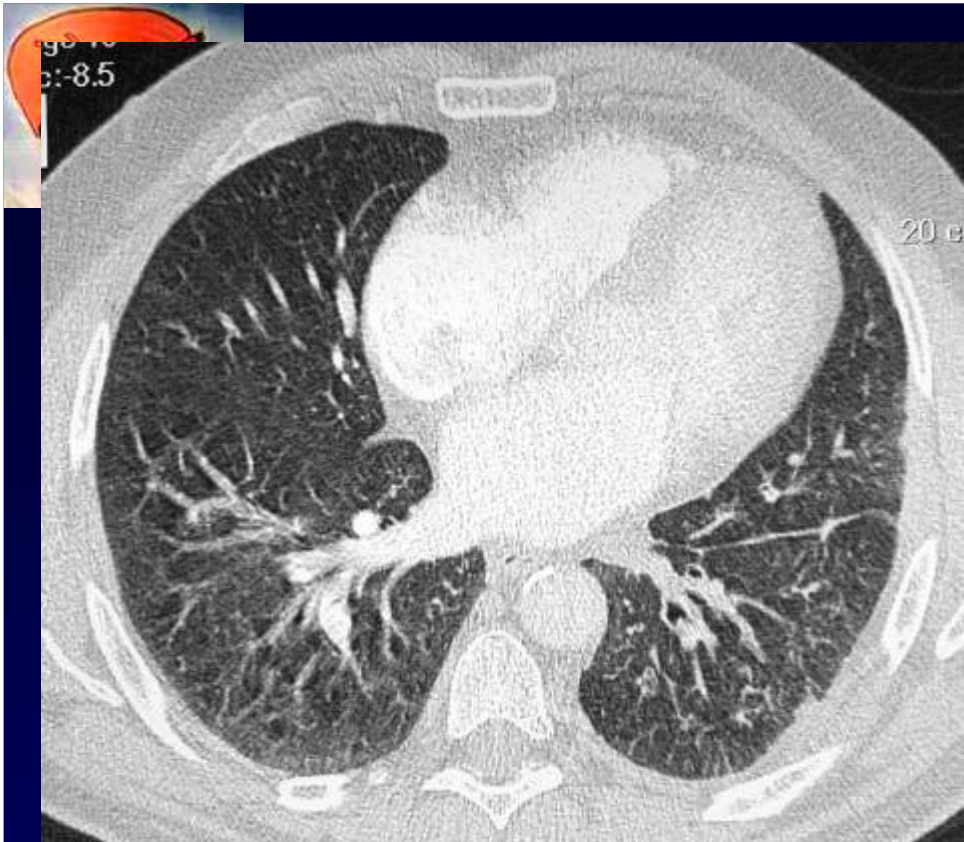
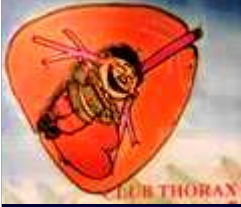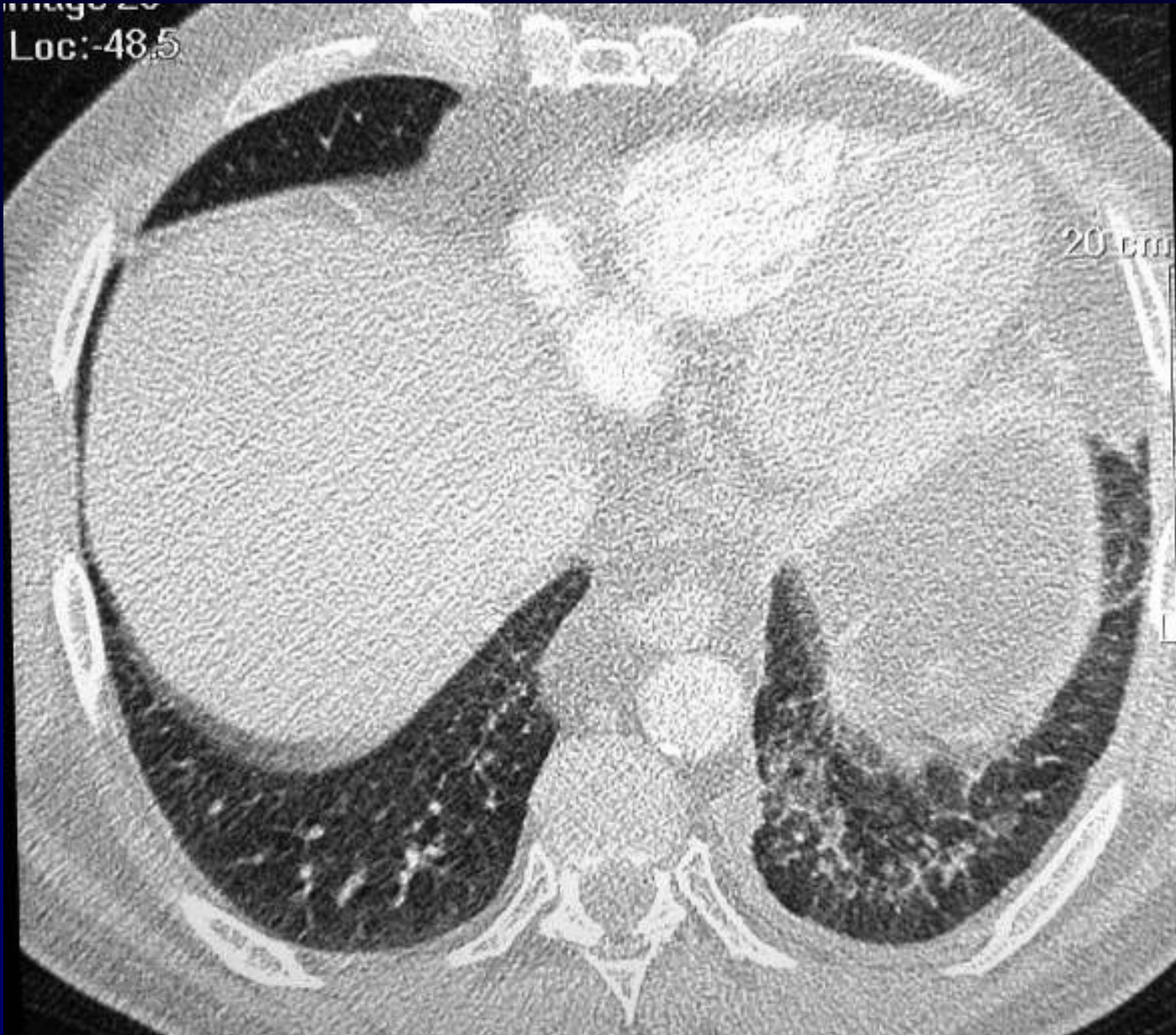
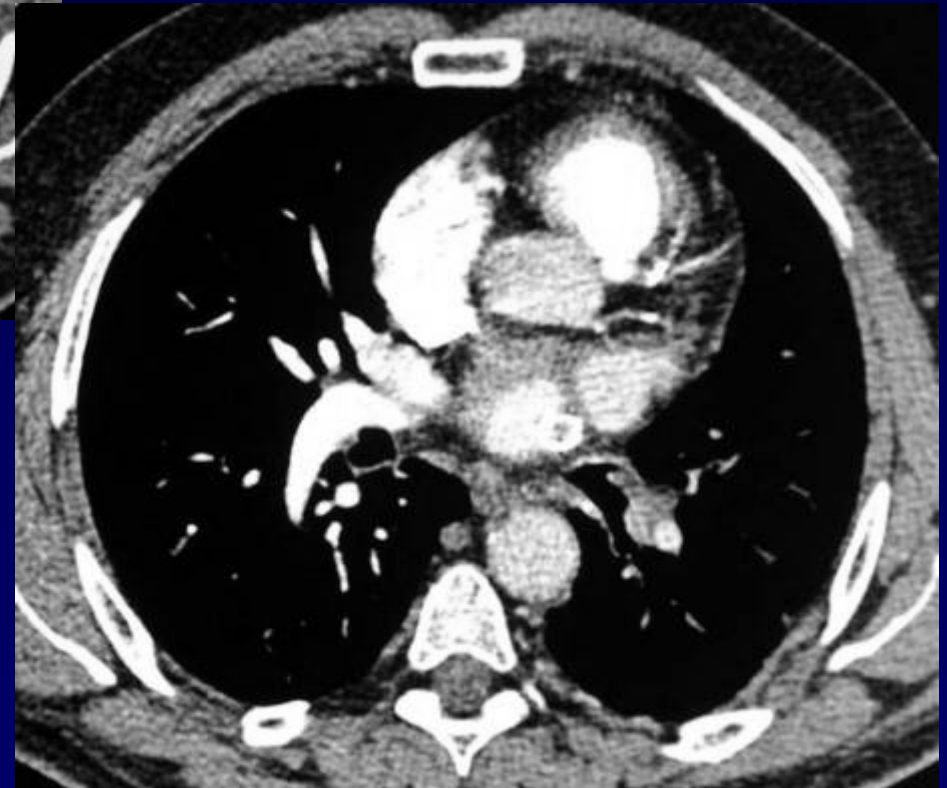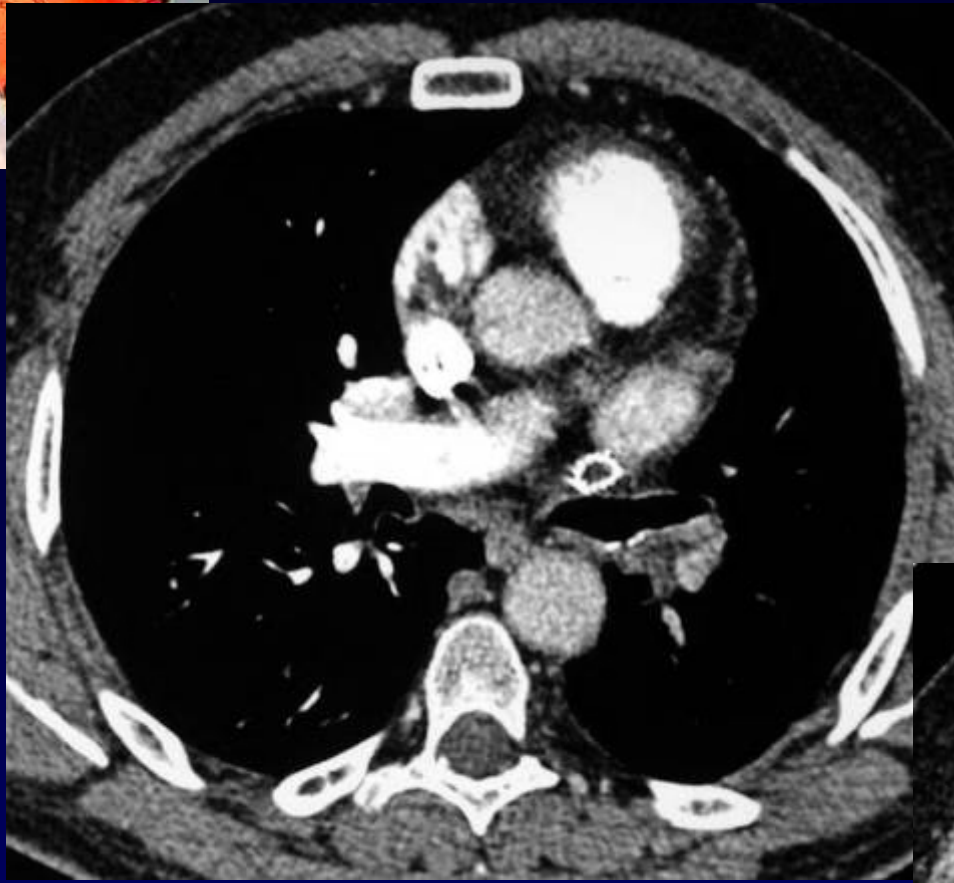
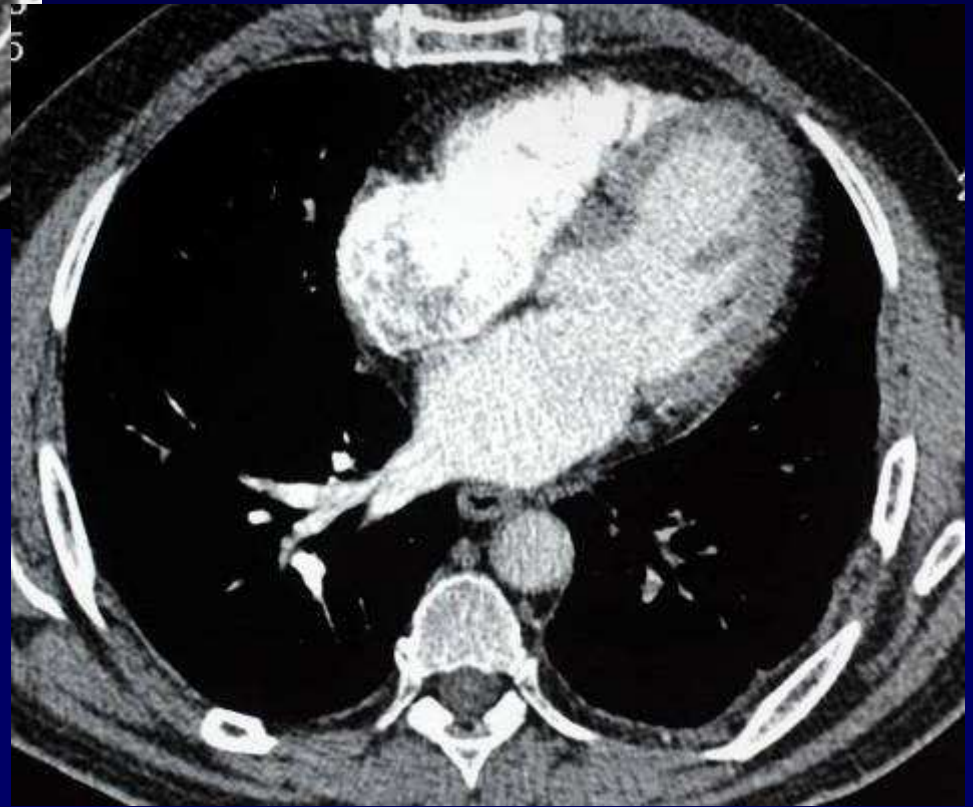
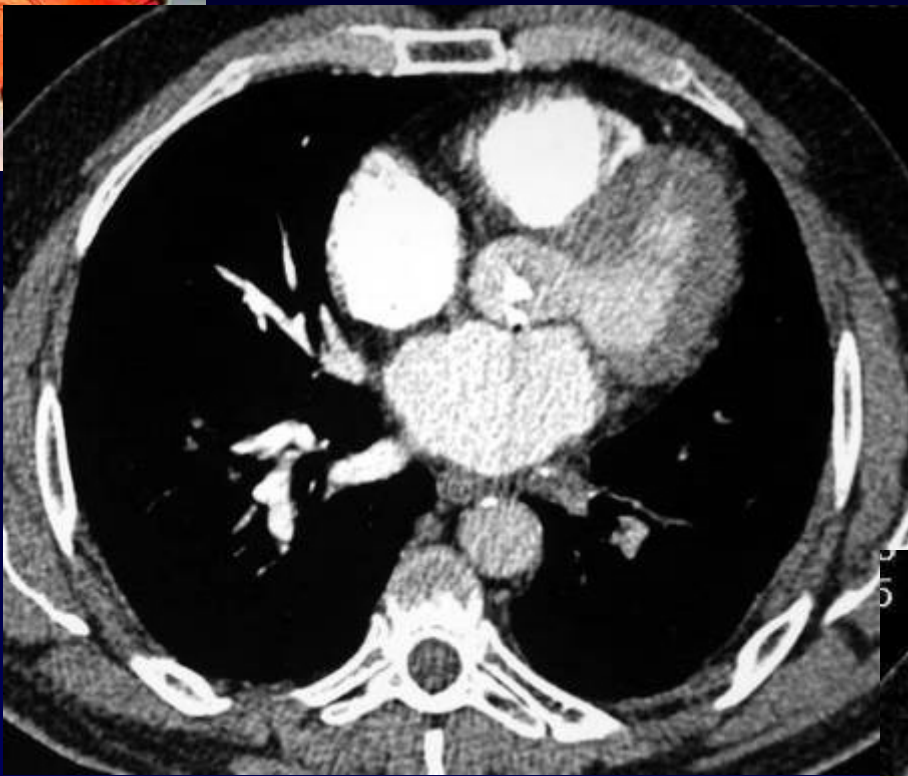


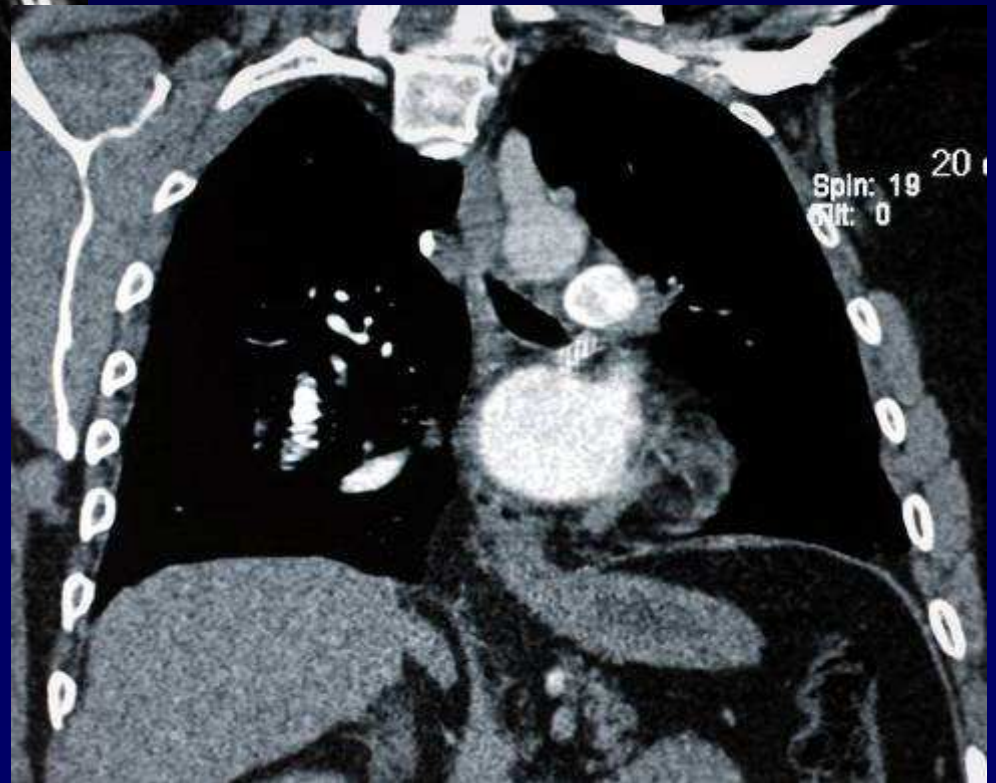
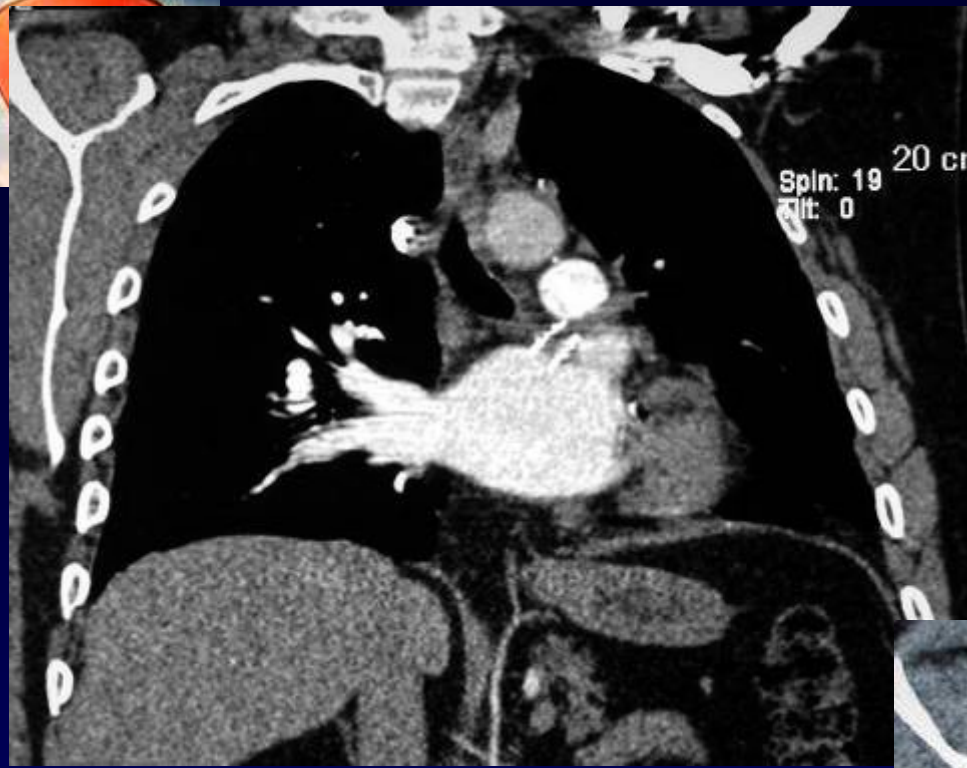

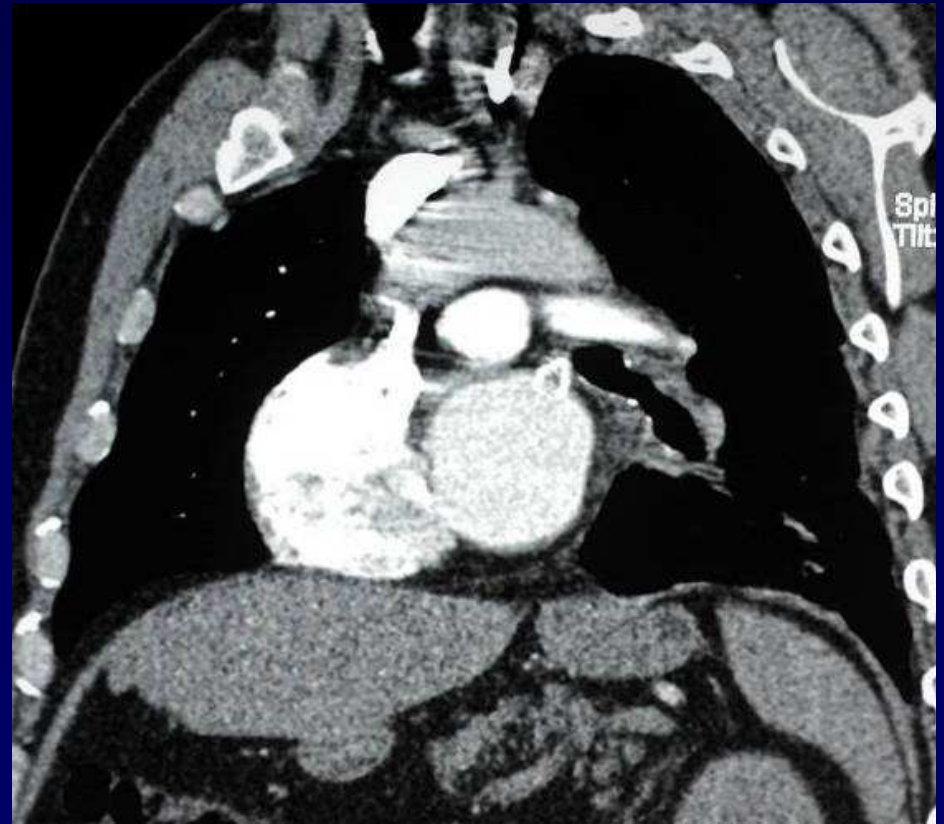
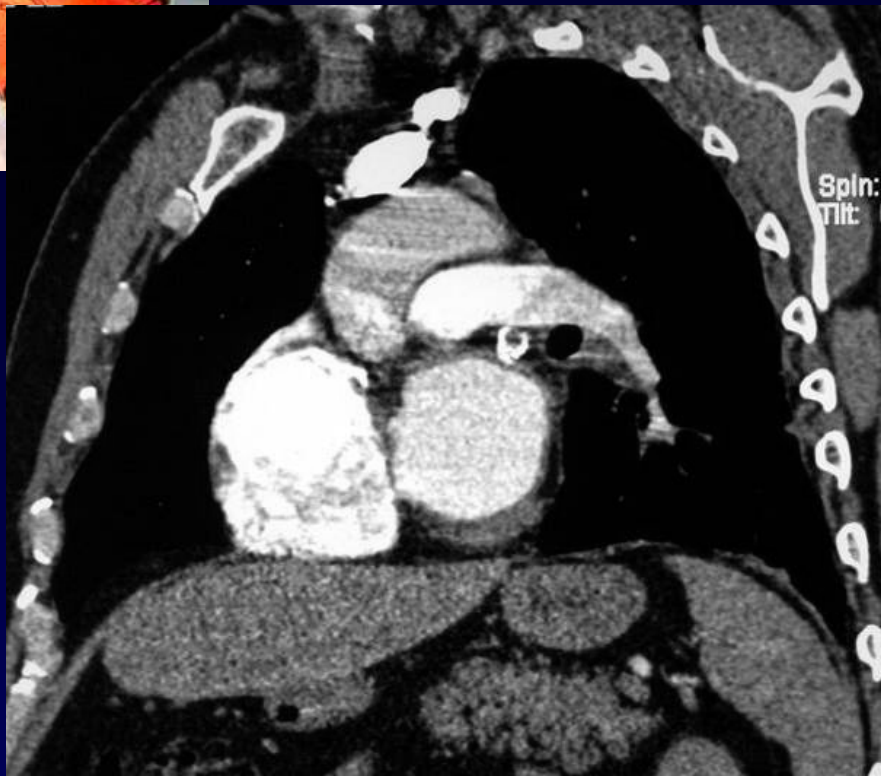
Image 20
Loc: -48.5

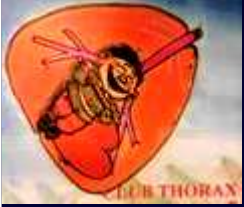











Diagnostic ?



Diagnostic

Stent de la veine pulmonaire lobaire supérieure gauche thrombosé

Veine pulmonaire lobaire inférieure gauche thrombosée

Flux hétérogène dans l'artère pulmonaire gauche simulant une embolie pulmonaire

Fibrose du parenchyme pulmonaire gauche

Codage : Poumon – Cardiovasculaire - Iatrogène



Discussion

Traitement ??

- Anticoagulation
- Tentative de désobstruction du stent (cutting balloon)
- pneumonectomie gauche
- Transplantation cœur – poumon.